

TREATMENT OF AN ACUTE DISC HERNIATION RESULTING IN RADICULOPATHY AND FOOT DROP USING HIGH POWER LASER THERAPY

Author: Joseph A. Costello Jr. DC, DABCO

CLASS IV LASER THERAPY CASE REPORT

OBJECTIVE:

To demonstrate the efficacy of High Power Laser Therapy as a treatment solution for a patient with an acute disc herniation non-responsive to traditional medical treatments.

HISTORY:

This patient is an adult male who injured his low back during a golf outing two months prior. His initial complaints included low back pain with radiation into his left lower extremity. At the time of presentation, he rated his pain as a ten on a visual analog pain scale. At the time of presentation, he had already completed several epidural steroid injections without relief.

CLINICAL EXAMINATION:

Height: 6'6" Weight: 260 lbs.

NEUROLOGICAL EXAMINATION:

DTR: 2/2 and symmetrical. Dermatomal sensation was intact. Myotomal evaluation revealed 4+/5 weakness to the left anterior tibialis muscle. Long tract signs show no beats of ankle clonus. Babinski's sign was flexor. Heel and toe walking revealed foot drop weakness/ fatigue to the left anterior tibialis.

ORTHOPEDIC EXAMINATION:

SLR was 25 degrees left and 35 degrees right with classic root tension signs on the left. The sciatic notch

was exquisitely tender on the left side. Springing maneuvers showed pain over the spinous processes at L3 and L4. Sitting Bechterew's performed with neck flexion and Valsalva's maneuver revealed leg pain into the left foot and toes. Femoral nerve stretch test did not reveal L4 root tension signs.

RADIOGRAPHIC FINDINGS:

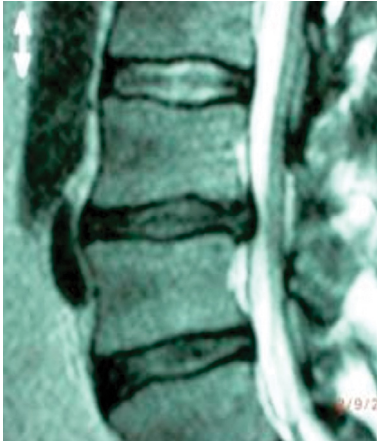MRI evaluation of the Lumbar spine was reviewed. This study consisted of both T1 and T2 weighted images in the sagittal and transaxial planes. There was a moderate central disc herniation at L3/4. Mild eccentric stenosis of the left IVF was also present (*see pre treatment images*).

TREATMENT PLAN (METHODS) AND RESULTS:

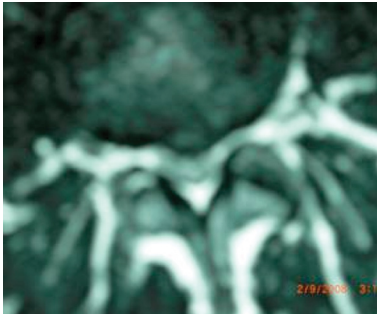
The patient underwent flexion/extension provocation testing. Complete centralization from his left lower extremity was achieved in neutral hyperextension of the lumbar spine. He was then treated in this static position with High Power Laser Therapy (5.0-7.5 watts for 10 minutes) to each of the following: L3/4 disc space, left sciatic notch, and left posterior tibial/common peroneal nerve, total dosage of 9,000-13,500 Joules per session. This patient received a total of ten treatment sessions with the high power laser. At the end of the treatment plan, he was asymptomatic with normal neurological and orthopedic findings. His foot drop had also resolved completely. (*See Table 1*)



PRE-TREATMENT RADIOGRAPHIC FINDINGS:



Pre-treatment T2 weighted saggital

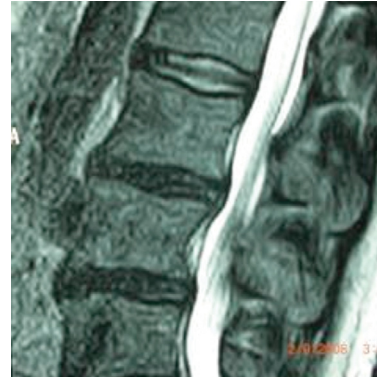


Pre treatment T2 weighted axial L3/4

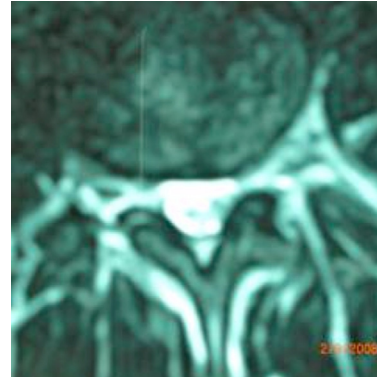
CONCLUSION:

High Power Laser Therapy has the ability to penetrate deeply and “bio stimulate” tissue to heal. Laser photonic stimulation has been shown to increase blood flow and lymphatic drainage while at the same time stimulating endorphin and enkephalin release for pain management⁸. Biostimulation translates into reduction of inflammation, and nerve regeneration^{5,6}. Regarding patients suffering from back and leg pain, the High Power Laser is thought to decrease inflammation of the disc and nerve root as well as aid in nerve regeneration⁵. Healing of annular defects in the outer 1/3 of the disc (which is vascularized) have the ability to heal⁹. Of interest in this particular case study is the fact that this patient has been followed for over 18 months. During that timeframe, he has not experienced any exacerbations of back or leg pain and has returned to all previous activities without pain!

POST TREATMENT RADIOGRAPHIC FINDINGS:



Post treatment T2 weighted saggital



Post treatment T2 weighted axial L3/4

High Power Laser Therapy also has the ability to reach deep within the body when compared to Low Level Laser Therapy⁸. Results achieved seem to be long term in nature when compared to all other forms of treatment for disc pathologies. This may also be due to the fact that laser energy appears to also biostimulate collagen and fibroblast growth which would enhance the tensile strength of the annular fibers of the degenerative disc patient^{1,2,3,4}. Clearly, further investigation regarding a large scale blinded study is necessary to further correlate patient’s clinical findings with pre and post imaging studies.

ASPEN

L A S E R S Y S T E M S

877-817-0365 • info@aspenslasers.com • aspenslasers.com

ABOUT THE AUTHOR

Dr. Costello is a Board certified chiropractic orthopedist. He is also Board certified in quality assurance and utilization review, and has been practicing continuously in Palm Beach County for 26 years. Dr. Costello was formerly the president Florida College of Chiropractic Orthopedist (1993 to 2005), and also the chief of clinical services Avicenna Laser Technology (April 2006 through September 2011). He is a published author and lecturer on Class IV laser therapy and clinical practice.

REFERENCES:

1. Effects of infrared laser exposure in a cellular model of wound healing. Skopin M and Molitor S, Dept. of Bioengineering, University of toledo, Toledo OH.
2. Mester E, Mester AF, Mester A (1985) The Biomedical effects of laser application. *Lasers Surg. Med.* 5:31-39.
3. The influence of low level infra red laser therapy on the regeneration of cartilage tissue. P Lievens, Ph. Van der Veen.
4. Therapeutic low energy laser improves the mechanical strength of repairing medial collateral ligament. Fung DT, Ng GY, Leung MC, Tay DK, *Lasers Surg Med.* 2002; 31: 91-96.

5. Double-blind randomized study evaluating regeneration of the rat transected sciatic nerve after suturing and postoperative low-power laser treatment. *Journal of Reconstructive Microsurgery.* 2001; 17 (2): 133-137. Shamir MH, Rochkind S, Sandbank J, Alon M.
6. Effects of laser irradiation on the spinal cord for the regeneration of crushed peripheral nerve in rats. *Lasers in Surgery and Medicine* 2001, 28(3): 216-219. Rochkind S, Nissan M, Alon M et al.
7. Assessment of laser therapy for late postoperative pain after lumbar fusion surgery and for pain and wound healing after acute traumatic injury – preliminary results. Biyani A, Skie M, Goel V, Ciocanel D, University of Toledo School of Medicine.
8. Class IV “High Power” laser therapy in Chiropractic and rehabilitation. Wertz R., *Dynamic Chiropractic* 2006 vol. 24, issue 23.
9. Vascularization of the intervertebral disc in pathological conditions. Moore R, University of Adelaide, Feb. 1995.

Source of Study: AspenLasers.com



877-817-0365 • info@aspenlasers.com • aspenlasers.com